FULL-LENGTH ORIGINAL RESEARCH

Positron emission tomography with α-[^{11}C]methyl-L-tryptophan in tuberous sclerosis complex–related epilepsy

*Sebastià Rubí, †Nicolas Costes, ‡§Rolf A. Heckemann, †¶Sandrine Bouvard, ‡§Alexander Hammers, #**Berta Martí Fuster, ††Karine Ostrowsky, ¶††Alexandra Montavont, ‡Julien Jung, *Xavier Setoain, ††Hélène Catenoix, ††Keiko Hino, †François Liger, †Didier Le Bars, and †¶††Philippe Ryvlin

Epilepsia, 54(12):2143–2150, 2013
doi: 10.1111/epi.12412

Sebastià Rubí, MD is a nuclear medicine specialist at Hospital Son Espases in Palma, Spain.

Summary

Objective: Tuberous sclerosis complex (TSC) is often associated with cerebral tubers and medically intractable epilepsy. We reevaluated whether increased uptake of α-[^{11}C]methyl-L-tryptophan (AMT) in cerebral tubers is associated with tuber epileptogenicity.

Methods: We included 12 patients (six male, 4–53 years old) with TSC and refractory seizures who were evaluated for epilepsy surgery in our center, including video-electroencephalographic (EEG) monitoring, fluid-attenuated inversion recovery magnetic resonance imaging (FLAIR MRI), and positron emission tomography (PET) with α-[^{11}C]methyl-L-tryptophan (AMT-PET). Nine of these 12 patients also underwent intracerebral EEG recording. AMT uptake in each tuber was visually evaluated on PET coregistered with MRI. An AMT uptake index based on lesional/healthy cortex ratio was also calculated. Sensitivity and specificity values of AMT-PET in the detection of epileptogenic lesions were obtained, using the available electroclinical and neuroimaging evidence as the gold standard for epileptogenicity.

Results: A total of 126 tubers were identified. Two of 12 patients demonstrated a tuber with clearly increased AMT uptake, one of whom also showed a subtle increased AMT uptake in another contralateral tuber. Four other patients showed only subtle increased AMT uptake. The only two tubers with clearly increased AMT uptake proved to be epileptogenic based on intracerebral EEG data, whereas none of the tubers associated with subtle increased AMT uptake were involved at ictal onset. In a per-patient approach, this yielded a sensitivity of clearly increased AMT uptake in detecting tuber epileptogenicity of 17% (2/12 patients), whereas the per-lesion sensitivity and specificity were 12% (95% confidence interval [CI]: 3–34%) and 100% (95% CI: 97–100%), respectively.

Significance: AMT-PET is a specific neuroimaging technique in the identification of epileptogenic tubers in TSC. Despite its low sensitivity, the clinical usefulness of AMT-PET still deserves to be considered according to the challenging complexity of epilepsy surgery in tuberous sclerosis.

KEY WORDS: α-[^{11}C]methyl-L-tryptophan, Positron emission tomography, Tuberous sclerosis, Epilepsy.

Accepted September 10, 2013; Early View publication October 28, 2013.

*Nuclear Medicine Department, Hospital Clinic, Barcelona, Spain; †CERMEP - Imagerie du Vivant, Lyon, France; ‡Neurodis Foundation, Lyon, France; §Division of Neuroscience and Mental Health, Faculty of Medicine, Imperial College London, London, United Kingdom; ¶TIGER, CRNL, INSERM U1028, CNRS 5292, Lyon, France; #Biophysics and Bioengineering Unit, Physiological Sciences Departament I, School of Medicine, University of Barcelona, Barcelona, Spain; **Biomedical Research Networking Center in Bioengineering, Biomaterials and Nanomedicine (CIBER-BBN), Barcelona, Spain; and ††Department of Functional Neurology and Epileptology and IDEE, Hospices Civils de Lyon, Lyon, France

Address correspondence Sebastià Rubí, Nuclear Medicine Department, Hospital Clinic, Villarroel 170, 08036 Barcelona, Spain. E-mail: s.rubi.sureda@gmail.com

Wiley Periodicals, Inc.
© 2013 International League Against Epilepsy

Tuberous sclerosis complex (TSC) is an autosomal dominant disorder characterized by hamartomas in various organs including the brain. About 70–90% of TSC patients develop epilepsy, most often characterized by drug-resistant seizures (Chu-Shore et al., 2010). Despite multiple cortical lesions, seizures often originate from a single tuber, for which surgical resection offers high rate of seizure freedom (Koh et al., 2000; Karenfort et al., 2002; Jarrar et al., 2004; Wu et al., 2010). However, the identification of the epileptogenic tuber remains a challenge. Indeed, standard neuroimaging methods, including fluid-attenuated inversion recovery magnetic resonance imaging (FLAIR MRI) and positron emission tomography (PET) with [^{18}F]fluorodeoxyglucose (FDG) cannot identify the tuber responsible for drug-resistant seizures (Rintahaka & Chugani, 1997; Pinto Gama et al., 2006). Conversely, functional MRI of epileptic spikes, diffusion tensor imaging, subtraction ictal single-photon emission computed tomography coregistered to MRI (SISCOM), and magnetoencephalography/magnetic source imaging (MEG/MSI) might help detecting the epileptogenic tuber (Koh et al., 1999; Iida et al., 2005; Jansen et al., 2006; Wu et al., 2006; Jacobs et al., 2008; Aboian et al., 2011; Tiwari et al., 2012). Similarly, PET with α-[^{11}C]methyl-L-tryptophan (AMT) was found to detect an increased uptake of AMT within the epileptogenic tuber, selectively, in about 50% of patients (Chugani et al., 1998b; Fedi et al., 2003; Kagawa et al., 2005) . Although AMT is a tryptophan analogue that physiologically depicts serotonin synthesis rate (Muzik et al., 1997; Chugani et al., 1998a; Fedi et al., 2001; Juhasz et al., 2003), its increased uptake in epileptogenic tubers seems to primarily reflect changes in the kynurenine pathway (Chugani & Muzik, 2000; Fedi et al., 2001; Juhasz et al., 2003; Chugani, 2011). So far, two centers have evaluated the diagnostic value of AMT-PET in patients with TSC, using comparisons with subdural electroencephalography (EEG) recordings and surgical outcome (Chugani et al., 1998b; Asano et al., 2000; Fedi et al., 2003; Kagawa et al., 2005; Tiwari et al., 2012). In a recent review, these authors appealed for studies from other centers to further assess the clinical utility of AMT-PET (Kumar et al., 2011).

Accordingly, the aim of our study was to reassess the diagnostic accuracy of AMT-PET in TSC patients, using stereoelectroencephalography (SEEG) findings and surgical outcome as reference data whenever possible.

Material and Methods

Patients and presurgical evaluation

We reviewed all patients with definite TSC who underwent presurgical evaluation for refractory epilepsy in our center, including AMT-PET. All investigations, including AMT-PET, were performed as part of the clinical work-up that was judged necessary to optimally localize the epileptogenic tuber to be resected. All patients, as well as their parents or caregivers when applicable, gave their informed consent to undertake these investigations, which were performed according to French ethical regulation.

Twelve patients were included (six male, median age 26 years, range 4–53 years), whose clinical features and tests performed in each of them are summarized in Table 1. All patients benefited from brain MRI and scalp video-EEG recording. MRI was performed using a 1.5 T Sonata scanner (Siemens Healthcare, Erlangen, Germany), and included a three-dimensional (3D) anatomic millimetric T_1-weighted sequence (repetition time [TR] 9.7 msec, echo time [TE] 4 msec) and a 3D fluid-attenuated inversion recovery (FLAIR) sequence (slice thickness 3 mm, TR/TE 8 s/105 msec, inversion time 2,200 msec). An axial turbo-spin echo T_2-weighted sequence (slice thickness 6 mm, TR/TE 2,260/90 msec) was also performed in eight patients. Additional noninvasive investigations were carried out in selected cases: FDG-PET (patients 1, 2, 4, and 7), SISCOM (patient 1), and MEG (patients 2 and 12).

Nine patients also underwent intracerebral EEG recordings using SEEG (Guenot et al., 2001). In four of these patients, SEEG was undertaken without any knowledge regarding AMT-PET findings (patients 1, 3, 4, and 6), since AMT-PET was performed after SEEG. In the remaining five patients (2, 5, 10, 11, and 12), AMT-PET findings were available at the time of SEEG, and could have theoretically influenced the placement of intracerebral electrodes. However, in all these nine patients, the general strategy was to place at least one electrode in any tuber considered potentially responsible for seizures, with a total of 8–16 (median = 12.5) implanted electrodes per patient. This could be readily achieved in six patients, where the number of implanted electrodes was equal to or exceeded that of the number of tubers. In the three remaining patients with 19–25 tubers, electrode placement was designed to allow several tubers to be sampled by the same electrode (e.g., ipsilateral mesial and lateral tubers aligned in the same coronal and axial planes), with the remaining nonimplanted tubers being placed in brain regions very unlikely to play a role in the patients' seizures according to their electroclinical features.

Previously to this AMT-PET study, three subjects had undergone a surgical procedure that failed to control seizures, including a thermocoagulation of the epileptogenic tuber in patients 3 and 4, and a left frontocentral corticectomy in patient 6. In all three patients, failure to control seizures was thought to reflect an epileptic tissue remnant within the previously identified epileptogenic zone, rather than mislocalizing intracerebral EEG data. Indeed the frontocentral resection performed in patient 6 could not remove part of the epileptic tuber located within the motor strip, and the volume of thermolesions achieved in patients 3 and 4 was smaller than that of the targeted tubers. The latter is in line with the view that thermolesion is a palliative

Table 1. Summary of clinical and AMT-PET data in the 12 patients included

Patient	Sex	Age	Number of tubers	Intracranial SEEG	Presumable epileptogenic tuber location[a]	Tubers with AMT-PET increased uptake[a]	Surgery after AMT-PET
1	F	42	19	Yes	Right anterior temporal (**0.98**) Left anterior temporal (**0.98**)	Subtle left frontal (**1.04**) Subtle left parietal (**1.08**) Subtle left occipital (**1.04**) Subtle right parietal (**1.01**)	No (because of bilateral foci)
2	F	28	3	Yes	Right frontal (**1.21**)	Clear right frontal (**1.21**)[b]	Right frontal tuber lesionectomy
3	F	53	5	Yes[c]	Left frontal (**1.0**)	Subtle left temporal (**1.12**)	No (because of eloquent cortex)
4	M	38	10	Yes[c]	Left frontal (**0.94**)	None	Awaits surgery
5	M	11	3	Yes	Right perisylvian (**1.11**)	Clear right perisylvian (**1.11**)[b] Subtle left parietal (**1.07**)	Awaits surgery
6	F	32	10	Yes[c]	Left central (**0.91**)	Subtle right central (**1.10**)	No further surgery (because of eloquent cortex)
7	M	19	6	No	Right frontal (**0.86**)	None	Awaits SEEG
8	M	28	6	No	Left temporal (**0.87**)	Subtle left temporopolar (**0.92**)	Awaits SEEG
9	M	24	7	No	Left frontal (two tubers: **0.86**/**0.95**)	None	Refused SEEG and surgery
10	M	7	10	Yes	Left frontal (two tubers: **0.92**/**0.94**)	None	Awaits surgery
11	F	4	25	Yes	Right temporal (three tubers: **0.86**/**0.90**/**0.93**)	None	Right temporal resection
12	F	5	22	Yes	Right frontal (**0.87**)	None	Right frontopolar tuber lesionectomy

[a]Value of semiquantitative index for each cited tuber is in bold in brackets.
[b]Epileptogenic hyperintense tubers.
[c]Patients already operated before AMT-PET, in whom SEEG was performed before this prior surgery.

rather than a curative procedure in most cases (Catenoix et al., 2008). Nevertheless, the above procedures might have been large enough to alter the AMT uptake in the epileptogenic tuber, an issue that needs to be considered in the interpretation of data.

Three patients have been operated following AMT-PET, with a postoperative follow-up of 9–23 months. Complete seizure freedom was achieved in two patients (2 and 12), whereas the other one (patient 11) continued to having seizures.

We classified each tuber as being epileptogenic or nonepileptogenic on the basis of the best electroclinical evidence available. Seizure-free outcome after a tuber resection was considered as definitive proof of epileptogenicity of that tuber. Tubers involved at seizure onset during SEEG were also considered epileptogenic. In patients for whom neither SEEG nor successful surgery was performed, epileptogenic tubers were those topographically concordant with scalp video-EEG data, as determined by consensus of a multidisciplinary clinical conference. Location and number of epileptogenic tubers in each patient are summarized in Table 1.

α-[^{11}C]methyl-L-tryptophan-PET

The methodology of tracer production has been described previously (Chakraborty et al., 1996). Patients fasted for 6 h prior to the tracer injection to establish stable plasma concentrations of tryptophan and large neutral amino acids for the duration of the study. α-[^{11}C]methyl-L-tryptophan (4 MBq/kg) was injected intravenously over 2 min. PET scans were acquired in 3D mode, using a CTI Exact HR+ (Siemens Healthcare) in the first six patients, and using a Siemens Biograph mCT/S64 (Siemens Healthcare) in the last six patients. Attenuation maps were derived from transmission scans obtained with either ^{68}Ge rod sources (Exact HR+), or CT scans (Biograph mCT/S64). A 60-min dynamic emission scan was performed with the acquisition starting immediately after radiotracer injection (24 frames: 14 × 30 s, 3 × 60 s, 4 × 300 s, 3 × 600 s). Sinograms were corrected for attenuation and scatter. CTI Exact HR+ images were then reconstructed with a filtered backprojection (FBP) algorithm (Hann filter, cutoff at 0.5 of Nyquist frequency), yielding volumes of 128 × 128 × 63 voxels with a size of 2.06 × 2.06 × 2.42 mm^3. For Biograph mCT/S64 studies, reconstruction was done with FBP incorporating time-of-flight information (FBP-TOF) with 4 mm Gaussian kernel postfiltering, yielding 24 brain volumes of 128 × 128 × 109 with a voxel volume of 2.04 × 2.04 × 2.03 mm^3. PET data from 30 to 60 min postinjection were summed and converted to units of Becquerel per cubic centimeter (Bq/cm^3). These images were used in the subsequent visual and quantitative analyses.

Detection of cortical tubers and AMT-PET visual analysis

Identification of cortical tubers was based on visual review of FLAIR and T_2 MRI sequences. All focal cortical

hyperintense lesions were considered cortical tubers. In cases where the hyperintensity bordered on, but did not clearly involve the cortex, the complex consisting of the focal lesion and its overlying cortex was defined as a tuber. Hyperintensities located deeper within the white matter were not considered part of the cortical tubers, since they typically correspond to migration lines or other nonepileptogenic abnormalities seen in TSC. MRI and FDG-PET scans were coregistered with AMT-PET data from the same patient using SPM8 software (Wellcome Trust Center for Neuroimaging, University College of London, London, United Kingdom). Coregistered PET and MR images were displayed for simultaneous review and interpretation using a previously validated application (Larrabide et al., 2010). We visually rated the degree of AMT tracer uptake inside each cortical tuber and its immediate vicinity by comparing the image intensity to the surrounding cortex and, where possible, to contralateral homotopic healthy cortex. Each lesion was assigned to one of the following ordered categories (see Fig. 1): clearly hypointense ("clear-hypo"), subtly hypointense ("subtle-hypo"), isointense ("iso"), subtly hyperintense ("subtle-hyper"), and clearly hyperintense ("clear-hyper"). This qualitative evaluation was carried out by consensus between two neuronuclear imaging experts (SR and PR) who were blinded to all other information on the subjects.

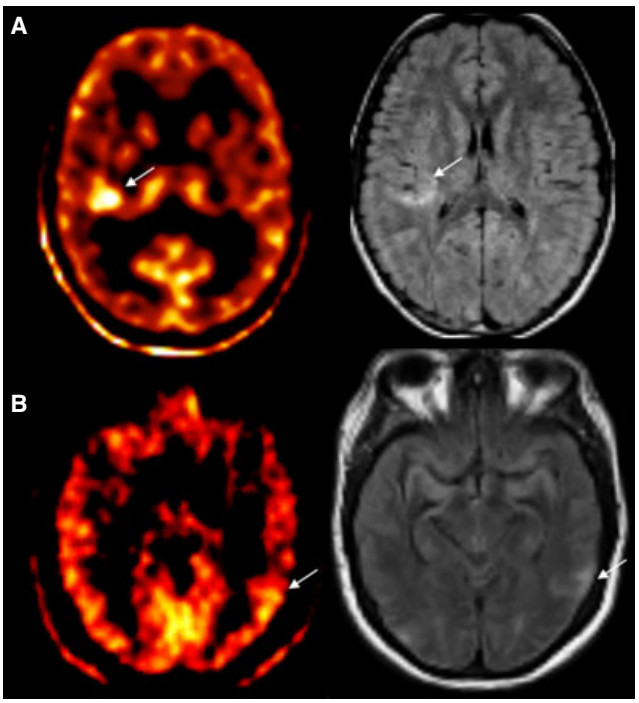

Figure 1.
Examples of clear and subtle visually increased AMT uptake in cortical tubers (arrows). (**A**) Clearly hyperintense ("clear-hyper") right perisylvian tuber in patient 5. (**B**) Subtly hyperintense ("subtle-hyper") left temporal tuber in patient 3. It is worth noting that the clearly hyperintense focus is already seen on a PET alone basis, whereas the subtle focus needs some prior knowledge of the underlying lesion on MRI to be outlined.
Epilepsia © ILAE

Regions of interest and semiquantitative analysis

Regions of interest (ROIs) were manually drawn by SR around all cortical tubers on FLAIR images using MRIcron software (Rorden & Brett, 2000), following delineation criteria identical to those described in the previous section for visual lesion detection. Anatomic segmentations were generated on T_1-weighted MR images using MAPER (multi-atlas propagation with enhanced registration [Heckemann et al., 2010]), using 30 atlases of healthy young adults (Hammers et al., 2003). This procedure yields 83 anatomic regions of interest (ROIs), including 62 cortical and 21 subcortical. By merging each subject's labeled volume with the labeled volume identifying the tubers, we obtained a final map that identified the anatomic region affected by each tuber, as well as all lesion-free regions. These maps were then coregistered to AMT-PET images by inversion of transform parameters from the MRI space to the AMT-PET space. Mean and maximum activity values (in Bq/ml) were determined for lesional and nonlesional ROIs. A semiquantitative index was calculated for each lesional tuber ROI, using the following formula: [tuber maximum activity value]/[average of the maximum activity values of all healthy cortical regions]. The healthy cortical regions were defined as the lesion-free portions of the 62 cortical regions provided by MAPER.

Data analysis

We explored the relationship between the visual interpretation of AMT-PET and the index values of semiquantitative analysis at a descriptive level and using the nonparametric trend test of Jonckheere-Terpstra. We evaluated the relationship between tubers' epileptogenicity and AMT uptake using chi-square test (or Fisher's exact test instead if required) for the categorical variables and Mann-Whitney *U* test for the quantitative variables ($p < 0.05$ was considered significant). Diagnostic accuracy of AMT-PET in detecting epileptogenic tubers was calculated for visual interpretation providing 95% confidence intervals (95% CIs) for sensitivity and specificity measures. Statistical procedures were performed using SPSS version 17.0 (SPSS Inc., Chicago, IL, U.S.A.).

Results

MRI and FDG-PET findings

In the 12 patients, 126 cortical tubers were detected on FLAIR MR images (median 8.5 tubers per patient; range 3–25; see Table 1). T_1- and T_2-weighted MRI images did not show additional tubers not visualized on FLAIR images. Tubers were distributed throughout both hemispheres in all patients. In the four patients (1, 2, 4, and 7) in whom

FDG-PET was performed, 25 of 38 tubers were visually normometabolic, mostly the smallest tubers (mean volume of 1.2 cc), whereas the other 13 showed various degrees of hypometabolism (mean volume of 2 cc).

α-[^{11}C]methyl-L-tryptophan-PET findings

Two of 12 patients demonstrated a tuber with clear visually increased AMT uptake, one of whom also showed a subtle increased AMT uptake in another contralateral tuber (see Table 1). Four other patients showed only subtle increased AMT uptake, restricted to a single tuber in three of them, but observed in four different tubers in the remaining patient. Among the 126 tubers observed, 2 (1.6%) were classified as "clear-hyper", 8 (6.3%) as "subtle-hyper", 64 (50.8%) as "iso", 10 (7.9%) as "subtle-hypo", and 42 (33.3%) as "clear-hypo" in the visual interpretation of AMT-PET images.

The relationship between visual and semiquantitative results is plotted in Figure 2, showing that the calculated index increased linearly across the five visual ordinal categories ($p < 0.05$). However, one "subtle-hyper" tuber displayed a higher index (1.12, patient 3) than the lowest index associated with a "clear-hyper" tuber (1.11, patient 5), with three other "subtle-hyper" tubers showing comparable values between 1.07 and 1.10.

Comparison of AMT-PET findings to tuber epileptogenicity

The only two tubers (in patients 2 and 5) with clear increase of AMT uptake proved to be epileptogenic based on SEEG data, yielding a per-patient sensitivity of clearly AMT increased uptake of 17% (2/12). This finding was confirmed by successful surgical resection in one patient, whereas the other is awaiting surgery.

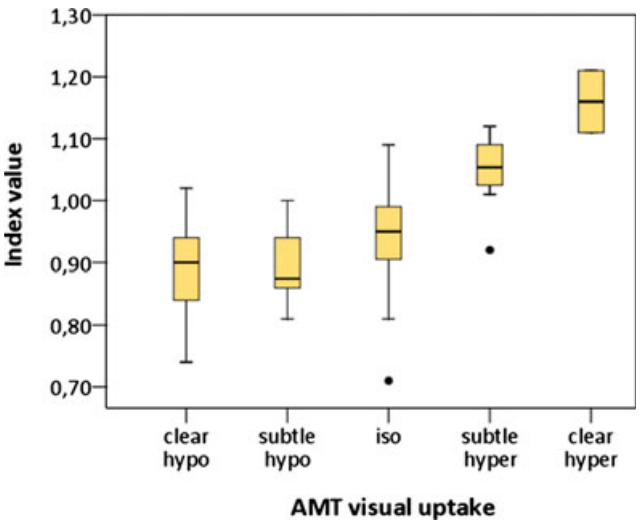

Figure 2.
Box plots showing the distribution of values of the semiquantitative index for each visual uptake category.
Epilepsia © ILAE

The situation was different for the eight "subtle-hyper" tubers observed in five different patients. Four of these patients underwent SEEG, which consistently showed that seizure onset did not occur at the site of the "subtle-hyper" tubers. In the fifth patient, who demonstrated a single "subtle-hyper" tuber in the left temporal pole, scalp video-EEG data suggested an ictal onset within another tuber located in the same lobe, but over the left Heschl's gyrus. However, this impression has not yet been confirmed by SEEG.

In the overall pool of 126 tubers, a statistically significant relationship ($p = 0.017$) between the presence of clearly increased uptake and epileptogenicity was demonstrated. The distribution of visual AMT-PET findings in both groups of tubers, epileptogenic and nonepileptogenic, is depicted in Table 2. The per-lesion sensitivity and specificity of clearly AMT increased uptake for epileptogenicity were 12% (95% CI 3–34%) and 100% (95% CI 97–100%), respectively. Conversely, the mean value of the semiquantitative index was slightly higher in the group of epileptogenic lesions (0.95 vs. 0.93), although this finding was not significant.

To date, three patients have been operated following AMT-PET, and two of them (2 and 12) are since seizure free. In one of them (patient 2), the AMT "clear-hyper" tuber whose involvement at seizure onset had been proved by SEEG was resected. The two others did not show any tuber with clear or subtle increased AMT uptake.

Discussion

AMT-PET experience in tuberous sclerosis comes primarily from two research groups based in Detroit (MI, U.S.A.) (Chugani et al., 1998b; Asano et al., 2000; Kagawa et al., 2005) and Montreal (QC, Canada) (Fedi et al., 2003). Our study partly confirms their experience, showing that clear increased AMT uptake is suggestive of an epileptogenic tuber, whereas demonstrating that more subtle increased AMT uptake has no such value, translating into a lower sensitivity of AMT-PET than that previously reported.

In this cohort of 12 patients with 126 tubers, where coregistration of AMT-PET and FLAIR MRI images offered an optimal evaluation of the AMT uptake of tubers, the overall proportion of tubers with any degree of visually detectable

Table 2. Relationship between visual AMT uptake and epileptogenicity for all 126 lesions studied

	AMT visual				
	Clear-hypo	Subtle-hypo	Iso	Subtle-hyper	Clear-hyper
Epileptogenic					
No	34	7	60	8	0
Yes	8	3	4	0	2

increased AMT uptake was 10/126 (7.9%), with only two of these (1.6%) displaying a high degree of uptake. Among the previous studies, none included a systematic visual differentiation between clear and mild AMT increased uptake in the way we did, and only Fedi et al. (2003) detailed in their methods a dedicated visual inspection of the AMT-PET images performed by independent observers, from which they confidently reported 4/38 (10.5%) tubers with increased uptake. The other authors (Chugani et al., 1998b; Asano et al., 2000; Kagawa et al., 2005) mostly based their AMT-PET images analysis on a semiquantitative approach by defining a tuber/surrounding cortex uptake ratio from the average activities inside each previously delineated ROIs. Asano et al. (2000) studied 18 children, including 9 already reported in (Chugani et al., 1998b), and found 39/258 (15%) of tubers to have increased AMT uptake defined as a ratio above 0.98. Kagawa et al. (2005) found 30/179 (16.8%) of tubers with increased uptake, defined as a ratio of at least 1.01. We also chose a ROI activity–based method to carry on our semiquantitative analysis, since it constitutes an adequate alternative to the more complex and invasive kinetic modeling approaches (Muzik et al., 1997; Chugani et al., 1998b; Okazawa et al., 2000; Fedi et al., 2003). The semiquantitative index used in our study significantly correlated with visual analysis but did not prove superior to the latter for detecting epileptogenic tubers. Furthermore, "clear" and "subtle" hyper tubers demonstrated overlapping values. One reason for this discrepancy could be the reference region, defined as the mean of the maximum values observed in the lesion-free portions of each of the brain cortical ROIs. Depending on the number and location of tubers in each individual patient, the distribution of the portions of healthy cortex used as a reference will differ. Because physiologic AMT uptake varies among the different brain regions, differences in those used as a reference might have an influence on our index and could explain lower values than expected in "clear-hyper" tuber, and/or higher than expected in "subtle-hyper." Another limitation of our semiquantitative method was the anatomically drawn ROIs used for delineating the tubers, the cortical borders of which can be elusive. This likely resulted in underestimating the extent of some tubers, including that where the area of subtle increased AMT uptake was located outside the corresponding tuber ROI, accounting for an outlying value for this category of AMT findings (see Fig. 2).

It is interesting to note that the four patients with FDG-PET had a high proportion of tubers classified as normometabolic, at odds with the general view that most tubers are hypometabolic. However, most of the normometabolic tubers were small-sized and actually smaller than those displaying hypometabolism. Although this finding could reflect less metabolic abnormalities in smaller tubers, it can also be explained by spilling-in phenomena in relation to partial volume effect.

We confirmed that tubers with clear increased AMT uptake corresponded to the seizure-onset zone as delineated by intracerebral EEG in the corresponding patients, one of whom was rendered seizure free following the surgical resection of this tuber, and the other awaits surgery. This implied a sensitivity of clear increase of AMT uptake for epileptogenicity of 17% in a per-patient approach, whereas in the overall pool of lesions the sensitivity and specificity were 12% and 100%, respectively. In contrast, none of the eight tubers displaying subtle increased AMT uptake proved epileptogenic, including seven that were investigated with intracerebral electrodes. These findings differ from those previously published in the field.

Asano et al. (2000) found at least one epileptogenic tuber with an AMT uptake ratio >0.98 in 15/18 (84%) patients, providing a sensitivity of 40.7% and specificity of 90.9%. However, they considered a tuber as epileptogenic when located in the same lobe as ictal onset determined by scalp EEG or subdural EEG, the latter being available in 5 of 18 patients. Kagawa et al. (2005) studied the correspondence between tubers with increased AMT uptake and ictal onset determined by subdural EEG in 14 patients and by scalp EEG in 3 patients. They found such a correspondence in 16/17 (94%) patients, by defining AMT increased uptake as a ratio value of at least 1.01. Among the 30 tubers with AMT increased uptake, 23 participated to ictal onset. Nineteen of the 30 tubers with AMT increased uptake were confirmed as epileptogenic by good outcome after surgical removal, whereas five others remained equivocal. These authors highlighted the fact that all tubers with a ratio ≥1.10 (11 tubers in 9 patients) were all unequivocally epileptogenic by surgical outcome, again stressing the relevance of clear AMT hyperintensity as an epileptogenic marker. From an ROC curve analysis based on the surgical outcome criteria, they obtained an uptake ratio cutoff >1.03 for epileptogenicity, yielding a sensitivity of 74% and a specificity of 100%. However, this ROC curve analysis was applied to the subset of 30 tubers with AMT increased uptake (ratio ≥ 1.01), rather than the entire tuber population, probably leading to overestimate sensitivity. The issue of mildly increased AMT uptake was briefly addressed by the authors. Some tubers with mild AMT hyperintensity (ratio < 1.03) seemed to be nonepileptogenic by surgical outcome criteria (i.e., seizure free despite nonresection), whereas several others proved responsible of seizures after surgical resection. This contrasts with our results, where none of the eight tubers with subtly increased AMT uptake was involved at ictal onset, as confirmed by SEEG in seven of them. Finally, Fedi et al. (2003) defined an epileptogenic tuber as the one best explaining the scalp EEG findings and seizure semiology, and reported four epileptogenic tubers with AMT increased uptake in eight patients. Their quantitative approach, based on kinetic modeling, demonstrated that epileptogenic tubers had higher mean uptake constant (K*)

values than nonepileptogenic tubers and homologous cortical regions in healthy controls.

The reasons for our relatively less encouraging findings are not straightforward. A possible influence of age and/or epilepsy duration could be surmised, given that a majority of our patients were adults, whereas the other studies were mostly based on pediatric populations. However, no other evidence supporting this hypothesis is currently available. In fact, the two patients with a clear increased AMT uptake delineating an underlying epileptogenic tuber included one adult and one child. Another possible explanation is that three of our patients underwent a thermocoagulation or a surgical resection prior to AMT-PET. Although these procedures did not control the patients' epilepsy, they might still have targeted an epileptogenic tuber while masking associated increased AMT uptake. However, others have used AMT-PET in patients with previous unsuccessful epilepsy surgery considered for reintervention, and showed that PET could detect increased AMT uptake at the vicinity of previously resected regions that corresponded to the remaining epileptogenic tissue (Juhasz et al., 2004). Partial volume effect represents another potential limitation, in particular for detecting increased AMT uptake in small tubers. Accordingly, some authors have excluded small tubers from their analysis (Kagawa et al., 2005). However, this is unlikely to account for the lower sensitivity of AMT-PET in our series, since as confirmed by our data, smaller tubers are usually not epileptogenic (Cusmai et al., 1990; Pascual-Castroviejo et al., 2012).

Finally, the gold standard used for defining epileptogenicity of tubers might account for part of the discordance between our findings and those from others. Invasive EEG was available in 9 of our 12 patients, a higher proportion than those of most previously published series (Chugani et al., 1998b; Asano et al., 2000; Fedi et al., 2003). Furthermore, we used an invasive EEG technique, SEEG, which allows investigating all or the great majority of tubers, bilaterally, including those placed in deeply located brain regions such as the mesial orbitofrontal cortex or the insula, thus providing more firm conclusion as to which tubers are truly epileptogenic. Such extensive coverage of tubers is usually not possible with grids, as used by others (Chugani et al., 1998b; Asano et al., 2000; Kagawa et al., 2005). According to these differences, our lack of sensitivity might partly reflect greater accuracy in identifying the epileptogenic tuber.

Although of limited sensitivity in our experience, the clinical usefulness of AMT-PET still deserves to be considered according to the challenging complexity of epilepsy surgery in tuberous sclerosis, and the high specificity of clear increased AMT uptake. Our findings also reinforce the need for developing other approaches, such as SISCOM, MEG/MSI, and diffusion-weighted MRI, which have been reported as promising for detecting epileptogenic tubers (Koh et al., 1999; Jansen et al., 2003; Wu et al., 2006; Aboian et al., 2011; Tiwari et al., 2012).

Acknowledgments

SR was supported by the Fundació Universitària Agustí Pedro i Pons, Universitat de Barcelona. Authors affiliated with the Division of Neuroscience and Mental Health, Faculty of Medicine, Imperial College London, United Kingdom, are grateful for support from the NIHR Biomedical Research Centre funding scheme. The authors would like to thank C. Tourvieille, F. Bonnefoi, F. Lavenne, D. Ibarrola, C. Vighi, F. Vey, and V. Berthier from CERMEP for their excellent technical assistance and Dorothée Ville for her clinical contribution.

Disclosure

None of the authors has any conflict of interest to disclose. We confirm that we have read the Journal's position on issues involved in ethical publication and affirm that this report is consistent with those guidelines.

References

Aboian MS, Wong-Kisiel LC, Rank M, Wetjen NM, Wirrell EC, Witte RJ. (2011) SISCOM in children with tuberous sclerosis complex-related epilepsy. *Pediatr Neurol* 45:83–88.

Asano E, Chugani DC, Muzik O, Shen C, Juhasz C, Janisse J, Ager J, Canady A, Shah JR, Shah AK, Watson C, Chugani HT. (2000) Multimodality imaging for improved detection of epileptogenic foci in tuberous sclerosis complex. *Neurology* 54:1976–1984.

Catenoix H, Mauguiere F, Guenot M, Ryvlin P, Bissery A, Sindou M, Isnard J. (2008) SEEG-guided thermocoagulations: a palliative treatment of nonoperable partial epilepsies. *Neurology* 71:1719–1726.

Chakraborty PK, Mangner TJ, Chugani DC, Muzik O, Chugani HT. (1996) A high-yield and simplified procedure for the synthesis of alpha-[11C] methyl-L-tryptophan. *Nucl Med Biol* 23:1005–1008.

Chugani DC. (2011) Alpha-methyl-L-tryptophan: mechanisms for tracer localization of epileptogenic brain regions. *Biomark Med* 5:567–575.

Chugani DC, Muzik O. (2000) Alpha[C-11]methyl-L-tryptophan PET maps brain serotonin synthesis and kynurenine pathway metabolism. *J Cereb Blood Flow Metab* 20:2–9.

Chugani DC, Muzik O, Chakraborty P, Mangner T, Chugani HT. (1998a) Human brain serotonin synthesis capacity measured in vivo with alpha-[C-11]methyl-L-tryptophan. *Synapse* 28:33–43.

Chugani DC, Chugani HT, Muzik O, Shah JR, Shah AK, Canady A, Mangner TJ, Chakraborty PK. (1998b) Imaging epileptogenic tubers in children with tuberous sclerosis complex using alpha-[11C]methyl-L-tryptophan positron emission tomography. *Ann Neurol* 44:858–866.

Chu-Shore CJ, Major P, Camposano S, Muzykewicz D, Thiele EA. (2010) The natural history of epilepsy in tuberous sclerosis complex. *Epilepsia* 51:1236–1241.

Cusmai R, Chiron C, Curatolo P, Dulac O, Tran-Dinh S. (1990) Topographic comparative study of magnetic resonance imaging and electroencephalography in 34 children with tuberous sclerosis. *Epilepsia* 31:747–755.

Fedi M, Reutens D, Okazawa H, Andermann F, Boling W, Dubeau F, White C, Nakai A, Gross DW, Andermann E, Diksic M. (2001) Localizing value of alpha-methyl-L-tryptophan PET in intractable epilepsy of neocortical origin. *Neurology* 57:1629–1636.

Fedi M, Reutens DC, Andermann F, Okazawa H, Boling W, White C, Dubeau F, Nakai A, Gross DW, Andermann E, Diksic M. (2003) Alpha-[11C]-methyl-L-tryptophan PET identifies the epileptogenic tuber and correlates with interictal spike frequency. *Epilepsy Res* 52:203–213.

Guenot M, Isnard J, Ryvlin P, Fischer C, Ostrowsky K, Mauguiere F, Sindou M. (2001) Neurophysiological monitoring for epilepsy surgery: the Talairach SEEG method. StereoElectroEncephaloGraphy. Indications, results, complications and therapeutic applications in a series of 100 consecutive cases. *Stereotact Funct Neurosurg* 77:29–32.

Hammers A, Allom R, Koepp MJ, Free SL, Myers R, Lemieux L, Mitchell TN, Brooks DJ, Duncan JS. (2003) Three-dimensional maximum probability atlas of the human brain, with particular reference to the temporal lobe. *Hum Brain Mapp* 19:224–247.

Heckemann RA, Keihaninejad S, Aljabar P, Rueckert D, Hajnal JV, Hammers A, Alzheimer's Disease Neuroimaging Initiative. (2010) Improving intersubject image registration using tissue-class information benefits robustness and accuracy of multi-atlas based anatomical segmentation. *Neuroimage* 51:221–227.

Iida K, Otsubo H, Mohamed IS, Okuda C, Ochi A, Weiss SK, Chuang SH, Snead OC. (2005) Characterizing magnetoencephalographic spike sources in children with tuberous sclerosis complex. *Epilepsia* 46:1510–1517.

Jacobs J, Rohr A, Moeller F, Boor R, Kobayashi E, LeVan Meng P, Stephani U, Gotman J, Siniatchkin M. (2008) Evaluation of epileptogenic networks in children with tuberous sclerosis complex using EEG-fMRI. *Epilepsia* 49:816–825.

Jansen FE, Braun KP, van Nieuwenhuizen O, Huiskamp G, Vincken KL, van Huffelen AC, van der Grond J. (2003) Diffusion-weighted magnetic resonance imaging and identification of the epileptogenic tuber in patients with tuberous sclerosis. *Arch Neurol* 60:1580–1584.

Jansen FE, Huiskamp G, van Huffelen AC, Bourez-Swart M, Boere E, Gebbink T, Vincken KL, van Nieuwenhuizen O. (2006) Identification of the epileptogenic tuber in patients with tuberous sclerosis: a comparison of high-resolution EEG and MEG. *Epilepsia* 47:108–114.

Jarrar RG, Buchhalter JR, Raffel C. (2004) Long-term outcome of epilepsy surgery in patients with tuberous sclerosis. *Neurology* 62:479–481.

Juhasz C, Chugani DC, Muzik O, Shah A, Asano E, Mangner TJ, Chakraborty PK, Sood S, Chugani HT. (2003) Alpha-methyl-L-tryptophan PET detects epileptogenic cortex in children with intractable epilepsy. *Neurology* 60:960–968.

Juhasz C, Chugani DC, Padhye UN, Muzik O, Shah A, Asano E, Mangner TJ, Chakraborty PK, Sood S, Chugani HT. (2004) Evaluation with alpha-[11C]methyl-L-tryptophan positron emission tomography for reoperation after failed epilepsy surgery. *Epilepsia* 45:124–130.

Kagawa K, Chugani DC, Asano E, Juhasz C, Muzik O, Shah A, Shah J, Sood S, Kupsky WJ, Mangner TJ, Chakraborty PK, Chugani HT. (2005) Epilepsy surgery outcome in children with tuberous sclerosis complex evaluated with alpha-[11C]methyl-L-tryptophan positron emission tomography (PET). *J Child Neurol* 20:429–438.

Karenfort M, Kruse B, Freitag H, Pannek H, Tuxhorn I. (2002) Epilepsy surgery outcome in children with focal epilepsy due to tuberous sclerosis complex. *Neuropediatrics* 33:255–261.

Koh S, Jayakar P, Resnick T, Alvarez L, Liit RE, Duchowny M. (1999) The localizing value of ictal SPECT in children with tuberous sclerosis complex and refractory partial epilepsy. *Epileptic Disord* 1:41–46.

Koh S, Jayakar P, Dunoyer C, Whiting SE, Resnick TJ, Alvarez LA, Morrison G, Ragheb J, Prats A, Dean P, Gilman J, Duchowny MS. (2000) Epilepsy surgery in children with tuberous sclerosis complex: presurgical evaluation and outcome. *Epilepsia* 41:1206–1213.

Kumar A, Asano E, Chugani HT. (2011) Alpha-[(11)C]-methyl-L-tryptophan PET for tracer localization of epileptogenic brain regions: clinical studies. *Biomark Med* 5:577–584.

Larrabide I, Omedas P, Martelli Y, Planes X, Nieber M, Moya JA, Butakoff C, Sebastián R, Camara O, De Craene M, Bijnens BH, Frangi AF. (2010) Gimias: an open source framework for efficient development of research tools and clinical prototypes. *Func Imaging and Modeling of the Heart, ser. Lecture Notes in Computer Science* 5528:417–426.

Muzik O, Chugani DC, Chakraborty P, Mangner T, Chugani HT. (1997) Analysis of [C-11]alpha-methyl-tryptophan kinetics for the estimation of serotonin synthesis rate in vivo. *J Cereb Blood Flow Metab* 17:659–669.

Okazawa H, Leyton M, Benkelfat C, Mzengeza S, Diksic M. (2000) Statistical mapping analysis of serotonin synthesis images generated in healthy volunteers using positron-emission tomography and alpha-[11C]methyl-L-tryptophan. *J Psychiatry Neurosci* 25:359–370.

Pascual-Castroviejo I, Hernandez-Moneo JL, Pascual-Pascual SI, Viano J, Gutierrez-Molina M, Velazquez-Fragua R, Quinones Tapia D, Morales Bastos C. (2012) Significance of tuber size for complications of tuberous sclerosis complex. *Neurologia* Dec 27 [Epub ahead of print].

Pinto Gama HP, da Rocha AJ, Braga FT, da Silva CJ, Maia AC Jr, de Campos Meirelles RG, Mendonca do Rego JI, Lederman HM. (2006) Comparative analysis of MR sequences to detect structural brain lesions in tuberous sclerosis. *Pediatr Radiol* 36:119–125.

Rintahaka PJ, Chugani HT. (1997) Clinical role of positron emission tomography in children with tuberous sclerosis complex. *J Child Neurol* 12:42–52.

Rorden C, Brett M. (2000) Stereotaxic display of brain lesions. *Behav Neurol* 12:191–200.

Tiwari VN, Kumar A, Chakraborty PK, Chugani HT. (2012) Can diffusion tensor imaging (DTI) identify epileptogenic tubers in tuberous sclerosis complex? Correlation with alpha-[11C]methyl-L-tryptophan ([11C] AMT) positron emission tomography (PET). *J Child Neurol* 27:598–603.

Wu JY, Sutherling WW, Koh S, Salamon N, Jonas R, Yudovin S, Sankar R, Shields WD, Mathern GW. (2006) Magnetic source imaging localizes epileptogenic zone in children with tuberous sclerosis complex. *Neurology* 66:1270–1272.

Wu JY, Salamon N, Kirsch HE, Mantle MM, Nagarajan SS, Kurelowech L, Aung MH, Sankar R, Shields WD, Mathern GW. (2010) Noninvasive testing, early surgery, and seizure freedom in tuberous sclerosis complex. *Neurology* 74:392–398.